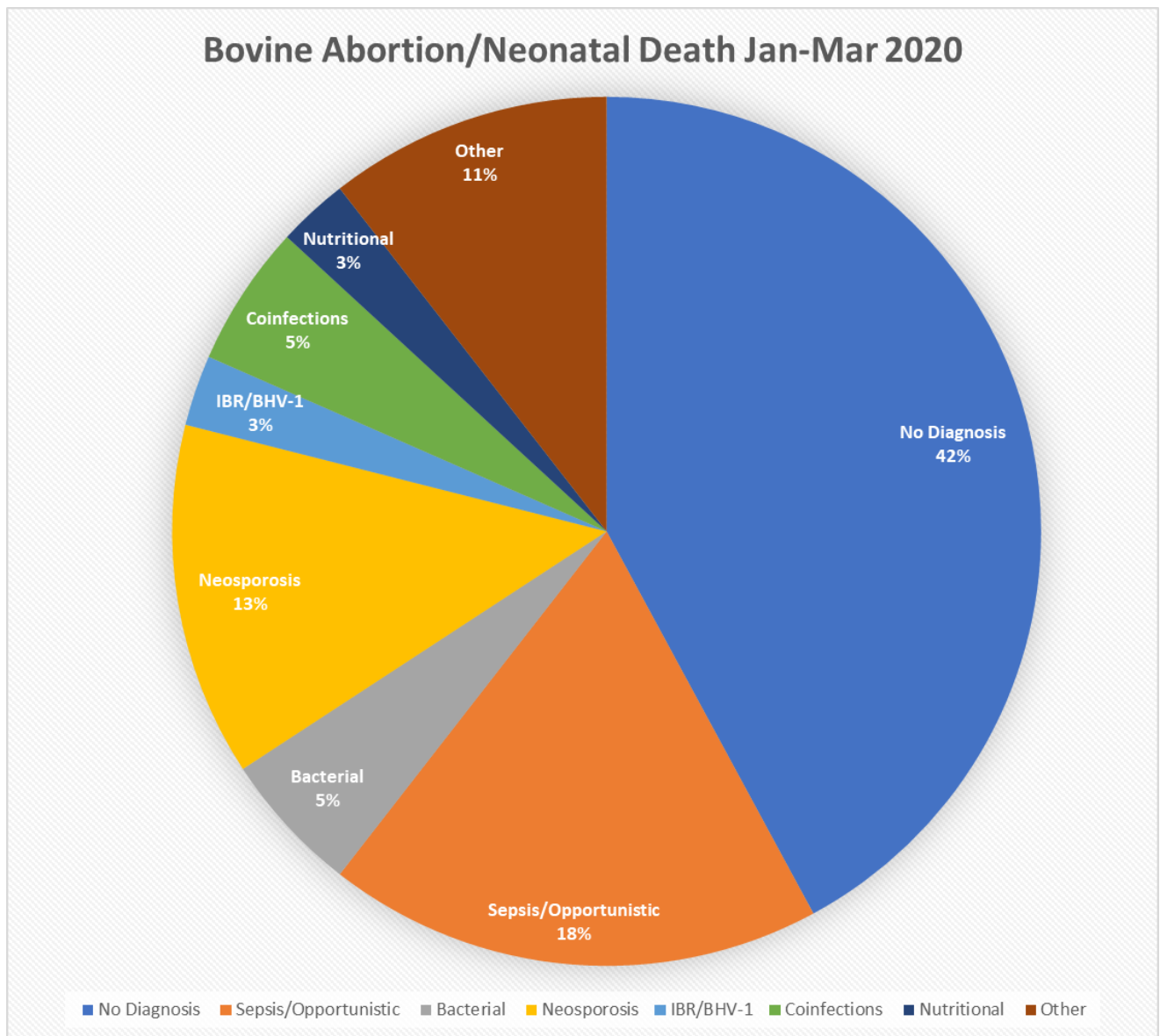


Spring 2020 Bovine Abortion/Neonatal Death Summary

Thirty-seven cases of bovine abortion, stillbirth, or neonatal death (defined as within the first week of life) presented to the MU VMDL between January 1st, 2020 and April 1st, 2020. These thirty-seven cases represent the examination of tissues or carcasses of thirty-eight bovine neonates/fetuses.

In 42% of cases, no cause of poor reproductive performance was identified. Details for all other categories are presented on the next page.



Sepsis/Oppportunistic:

Neonatal deaths included in this category presented as omphalitis, enteritis, meningitis, or a combination thereof, with various pathogens detected including: *E-coli* and *Salmonella*. It is likely that many of the cases in this category involved some degree of failure of passive transfer.

Neosporosis:

Neospora caninum was considered the probable cause of abortion, stillbirth, or neonatal death in five cases during the reporting period in 2020, compared with a single case in 2019. In three cases, *N. caninum* was detected in fetal tissues or placenta by qPCR. In one case, *N. caninum* was detected in fetal tissues by qPCR and protozoal cysts were seen on microscopic examination of the brain. In one case, *N. caninum* was suspected due to positive serologic results on fetal pleural and peritoneal fluid, however PCR testing was negative. It should be noted that two of these positive cases originated from the same herd.

Bacterial:

Helcococcus ovis and *Bacillus licheniformis*, both reported in the literature to be associated with bovine abortion, were each cultured from the abomasal contents in one case. Bacterial infections secondary to immunocompromise/FPT were not included in this category.

Infectious Bovine Rhinotracheitis (IBR/ BHV-1):

IBR antigen was detected by PCR and immunohistochemistry in one case, and was considered to be the cause of reproductive failure.

Coinfections (two pathogens identified):

One case was considered to be a *Trueperella pyogenes* and pathogenic *Leptospira spp.* coinfection. *Trueperella pyogenes* was cultured and PCR on the placental tissue returned positive for pathogenic *Leptospira spp.* The second case was positive by PCR for both *Neospora caninum* and pathogenic *Leptospira spp.*

Nutritional:

A single case during this 2020 reporting period was considered to have a nutritional component, compared with eight cases during the same period in 2019. Trace mineral deficiencies were identified via ICP-OES on fetal tissues in one case. This may suggest an improvement in available forage quality, relative to the previous year.

Other:

This category consists of four total cases. One case presented with congenital abnormalities (meningocele and cranium bifida). One case was suggestive of dystocia, with moderate subcutaneous edema present in the pelvic limbs. One case was suggestive of hypothermia, due to observed hemorrhage and edema consistent with vascular damage. The cause of death in the final case was considered to be esophageal groove dysfunction.

Please contact Dr. Lauren Delaney at delaneyle@missouri.edu with questions or comments about this data summary.